

## Ankle Injuries

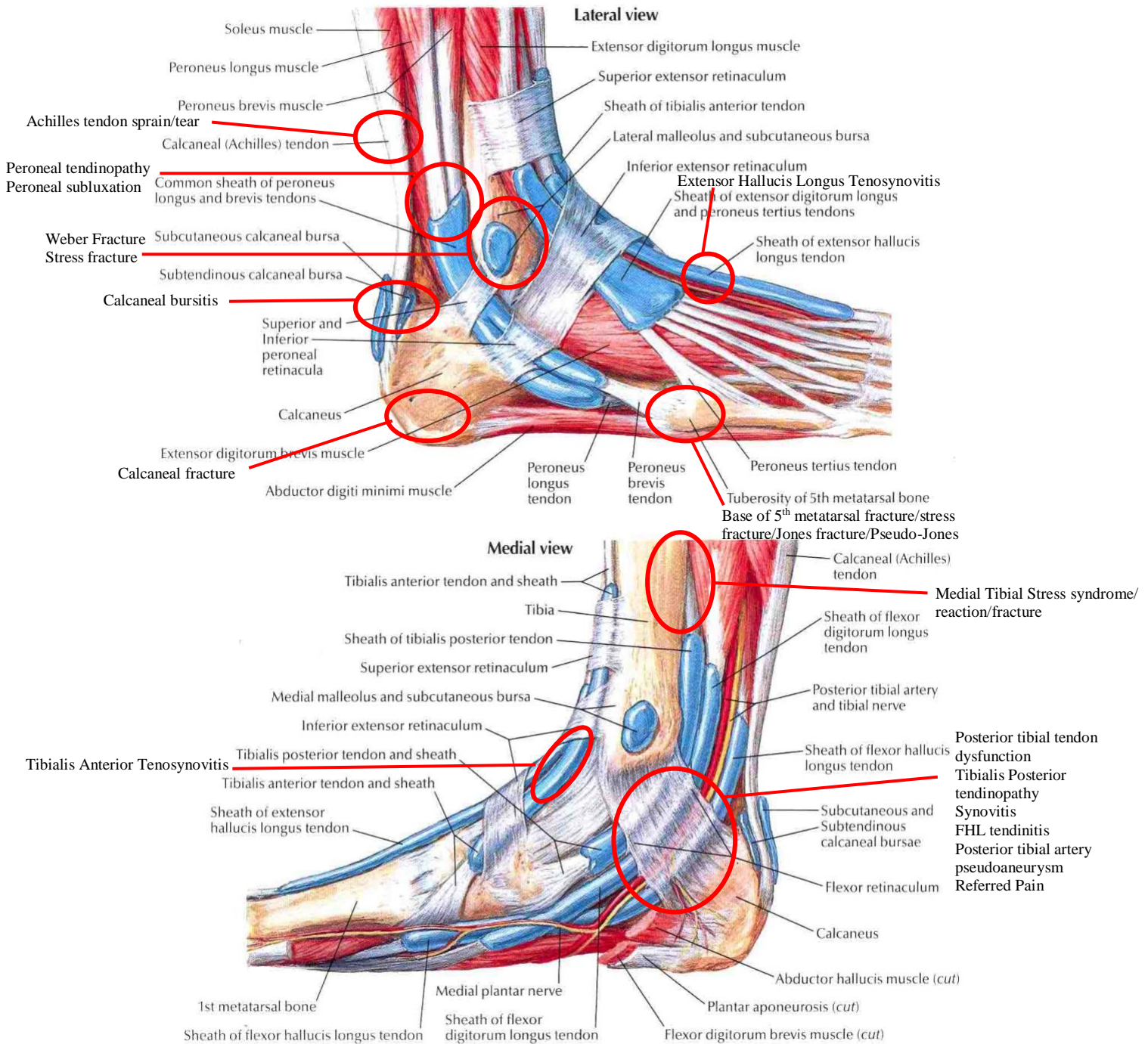
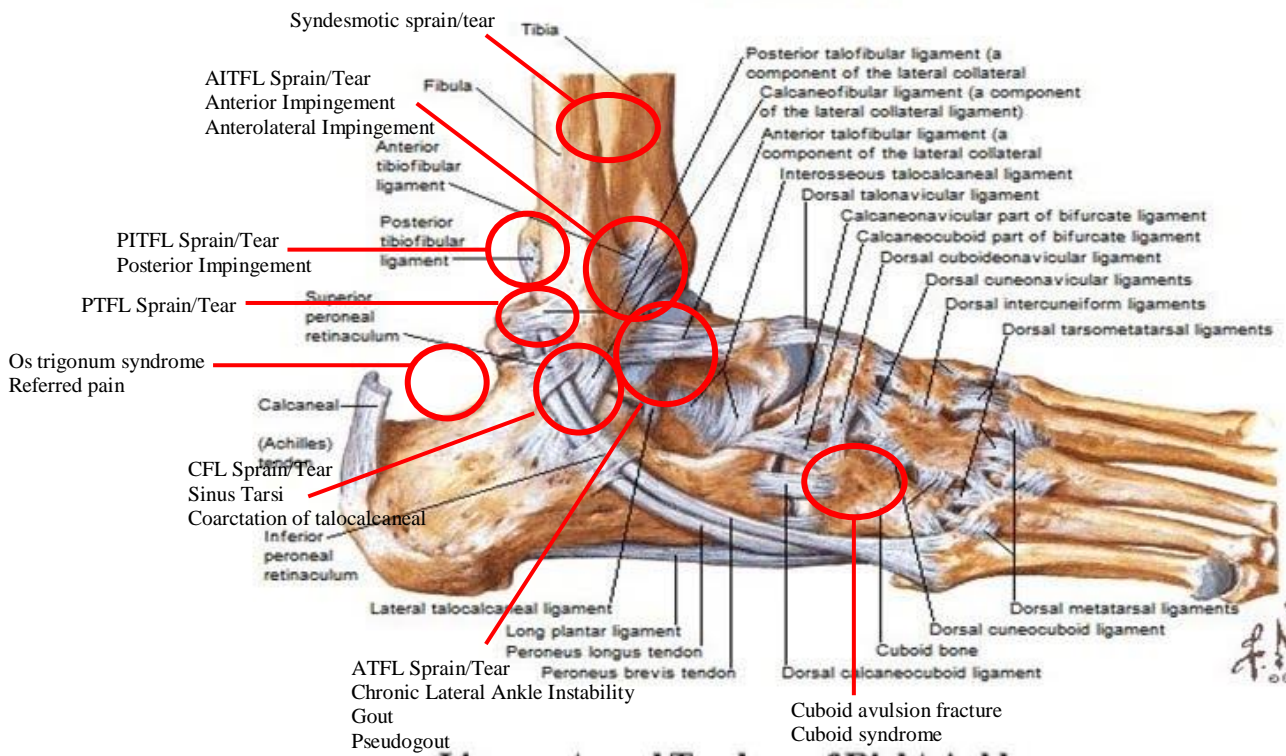
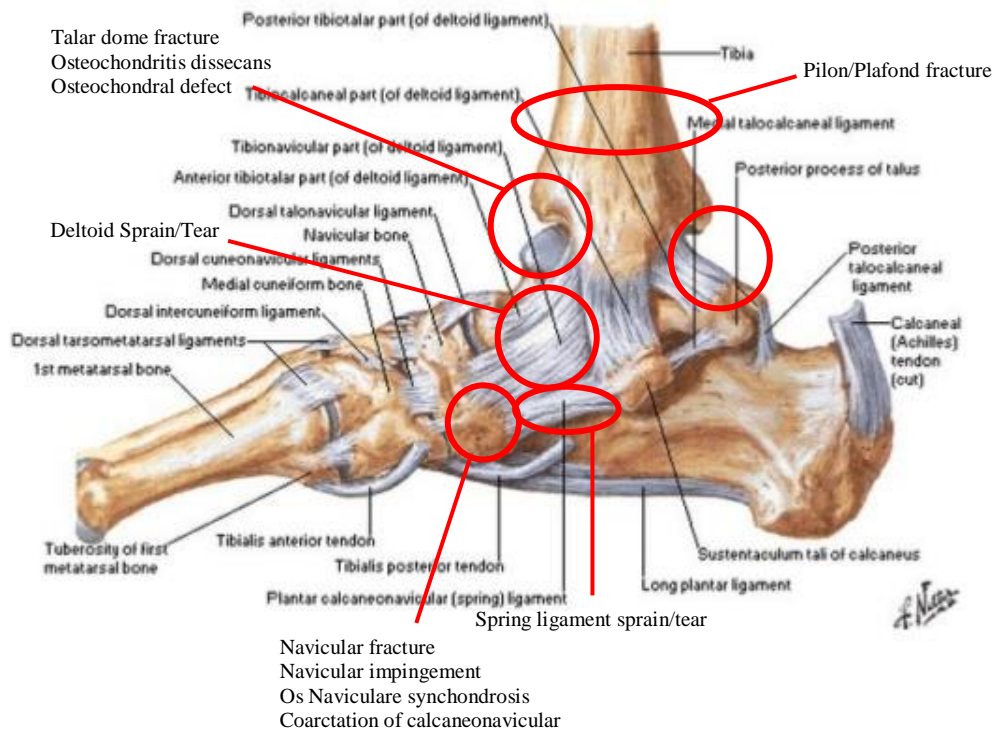


Image retrieved from: <https://humananatomychart.com/anatomy-of-the-foot-ligaments-and-tendons/>  
anatomy-of-the-foot-ligaments-and-tendons-foot-anatomy-tendons-ankle-anatomy-ligaments-and-tendons-ankle/

### Ligaments and Tendons of Right Ankle Lateral View



### Ligaments and Tendons of Right Ankle Medial View



Injury:	# of cases seen	Age/Gender	Sport Type	Comments
<b>Anterior</b>				
Anterior talofibular ligament (ATFL) sprain or tear				
Tibialis anterior tenosynovitis (skate bite)				
Extensor Hallucis tenosynovitis (skate bite)				
Anterior inferior tibiofibular ligament (AITFL) sprain or tear				
Anterior impingement				
Talar dome fracture				
Osteochondral defect/ Osteochondritis dissecans				
<b>Lateral</b>				
ATFL sprain or tear				
Chronic lateral ankle instability				
Anterolateral impingement syndrome				
Posterior impingement syndrome				
Weber fractures				
Fibular stress fracture				
Talar dome fracture				
Osteochondral defect/ Osteochondritis dissecans				
Peroneal tendinopathy				
Peroneal subluxation				
Calcaneofibular ligament (CFL) sprain/tear				
Sinus tarsi				
Cuboid syndrome				

Cuboid avulsion fracture				
Base of the 5 <sup>th</sup> metatarsal fractures (acute fracture/Stress fracture/Jones fracture/pseudo-Jones fracture)				
Referred pain from lumbar spine, peroneal nerve, or STFJ				
<b>Medial</b>				
Deltoid sprain/tear				
Tibialis Posterior tendinopathy				
Posterior tibial tendon dysfunction				
Spring ligament sprain/tear				
Synovitis, joint effusion				
Medial tibial traction syndrome/stress reaction/fracture				
Navicular fracture				
Navicular impingement				
Os Naviculare synchondrosis				
Flexor Hallucis longus tendinopathy				
Posterior tibial artery pseudoaneurysm				
Referred pain from lumbar spine				
<b>Posterior</b>				
Achilles tendinopathy/tear				
Os trigonum syndrome				
Posterior inferior tibiofibular ligament (PITFL) sprain or tear				
Posterior talofibular ligament (PTFL) sprain or tear				
Pilon/Plafond fracture				



Posterior impingement				
Calcaneal bursitis				
Calcaneal fracture				
<b>Other</b>				
Syndesmotic sprain/tear				
Coarctation of talocalcaneal				
Coarctation of calcaneonavicular				
Gout				
Pseudogout				
Complex regional pain syndrome				