

Sports and Exercise Medicine

Differential Guide



2020/21

Radiology/Investigation Version

Authors: Dr. A Francella, Dr. N Dilworth

Contributors: Dr. K Asem, Dr. A Cantarutti, Dr. H Chen, Dr I Cheng, Dr. W Clayden, Dr. R Eardley, Dr. L Hillier, Dr. S Kraft , Dr. D Lawrence, Dr. M Leung, Dr K Lundine, Dr. D Nguyen, Mr. T O'Neill, Dr. T Rindlisbacher

Table of Contents	
Face/Head	Pages 2-5
Cervical Spine	Pages 6-8
Shoulder	Pages 9-11
Elbow	Pages 12-15
Wrist	Pages 16-17
Hand	Pages 18-19
Thoracolumbar	Pages 20-21
Hip	Pages 22-24
Knee	Pages 25-28
Ankle	Pages 28-32
Foot	Pages 33-35
Other	Pages 36-39
Dermatology	Pages 40-41

Face/Head Injuries

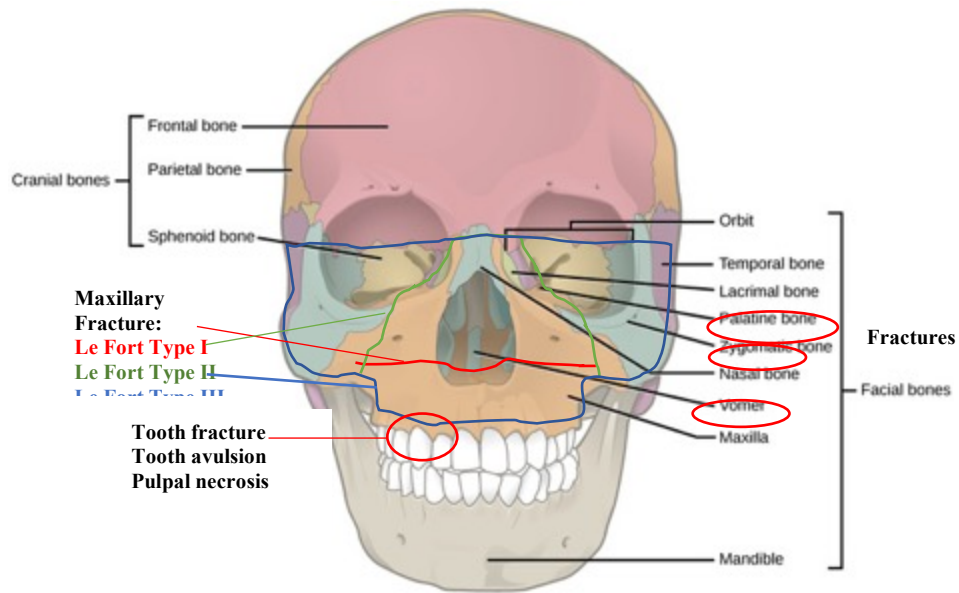


Image retrieved from: <https://courses.lumenlearning.com/boundless-biology/chapter/types-of-skeletal-systems/>

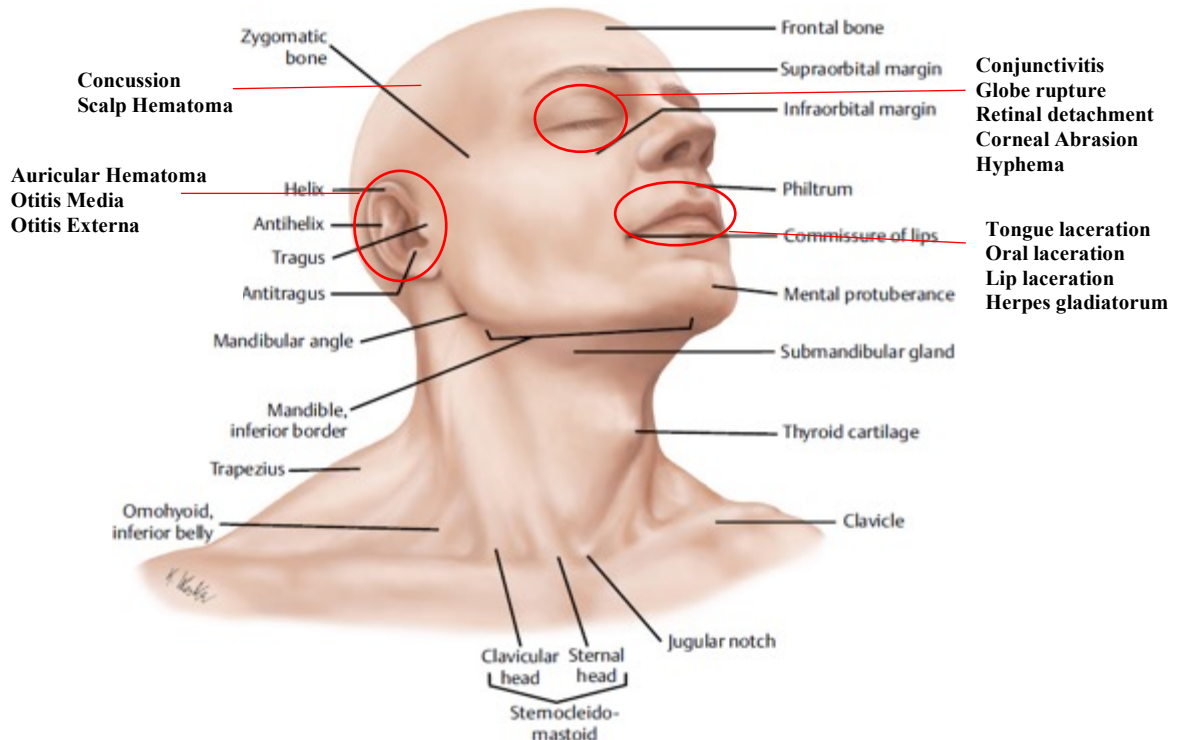


Image retrieved from: <http://heritance.me/surface-anatomy-of-skin/surface-anatomy-of-skin-neck-plastic-surgery-key>

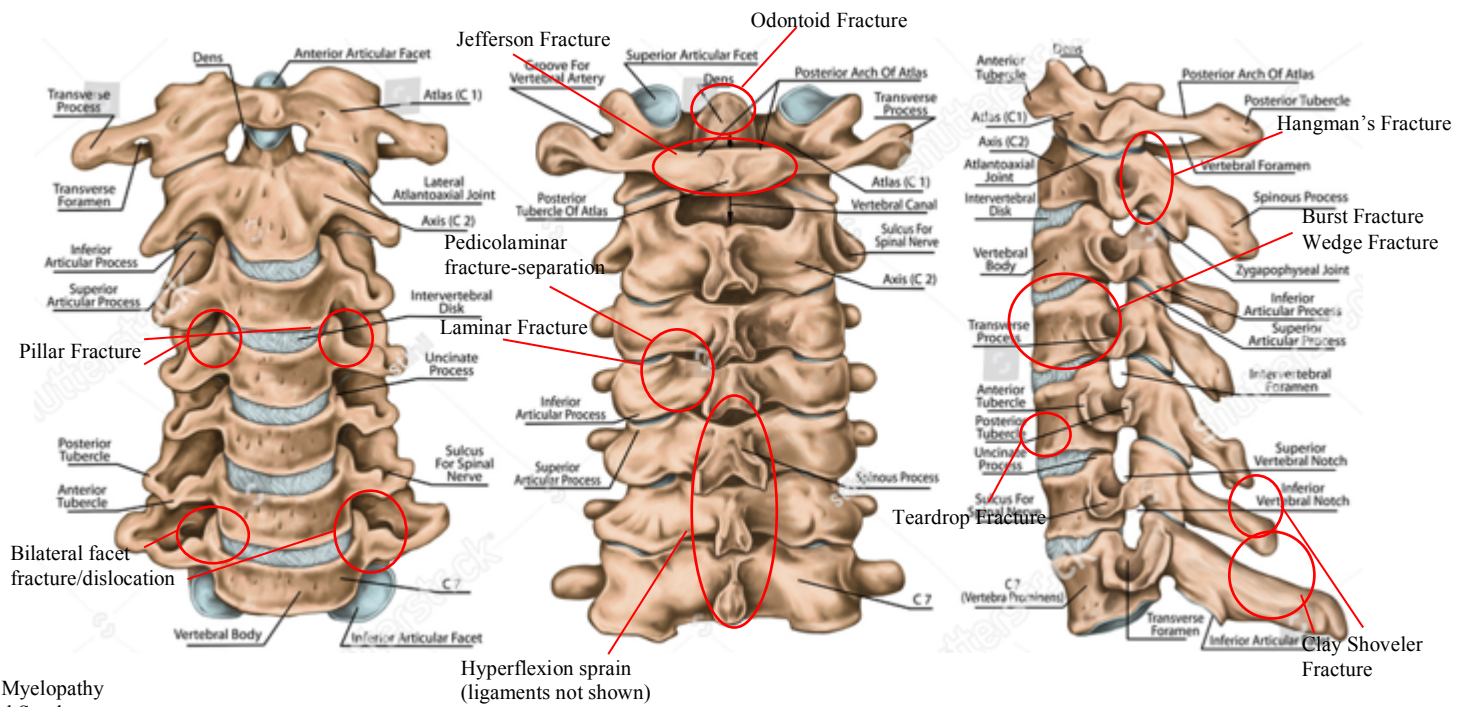
Sports & Exercise Medicine Differential Guidebook©
 Dr. A Francella, Dr N Dilworth 2020/21©

Injury: Fractures	# of cases seen	Age/Gender	Sport Type	INVESTIGATION
Orbital fracture				CT scan
Maxillary fracture: Le Fort Type I Le Fort Type II Le Fort Type III				CT scan Facial xrays
Nasal Fracture				Nasal xray
Mandibular Fracture				Mandibular xrays, CT scan
Zygomatic Arch Fracture				CT scan
Head				
Auricular hematoma				CT head rules
Scalp hematoma				CT head rules
Concussion				* http://sportmedschool.com/concussion/ Imaging indications
Otitis Externa				If malignant – may require CT Head, MRI
Otitis Media				
Herpes Gladiatorum				
Tympanic Membrane Rupture				
Dental				
Tooth fracture				Xray – Dental – DENTIST
Tooth avulsion/luxation				Xray – facial, dental - DENTIST
Tongue laceration				
Oral laceration				
Pulpal necrosis				
Lip laceration				Consider plastics referral/ER

Ocular				
Conjunctivitis				
Globe rupture				CT scan – r/o assoc. orbital fracture
Blunt Globe trauma				CT scan – r/o assoc. orbital fracture
Glaucoma				Tonometer
Retinal detachment				Fundoscopy, US with tegaderm
Corneal abrasion				Slit lamp
Hyphema				Slit lamp, tonometer, +/- CT scan r/o assoc. orbital fracture
Corneal Laceration				
Traumatic Iritis				Tonometer, CT scan – r/o assoc. orbital fracture
Traumatic Retinitis				Tonometer, CT scan – r/o assoc. orbital fracture

Intracranial/Spinal Column				
Chiari Malformation				MRI Head and Neck(preferred), CT Head
Subdural hematoma				CT head
Subarachnoid hematoma				CT head, +/- lumbar puncture
Epidural hematoma				CT head
Syringomyelia				MRI Cspine
Intracranial Hypertension				MRI head, Lumbar puncture pressures – NEUROLOGY referral
Vertebral Arterial Dissection				CTA Head/neck, MRA
Meningitis				Lumbar puncture +/- CT head

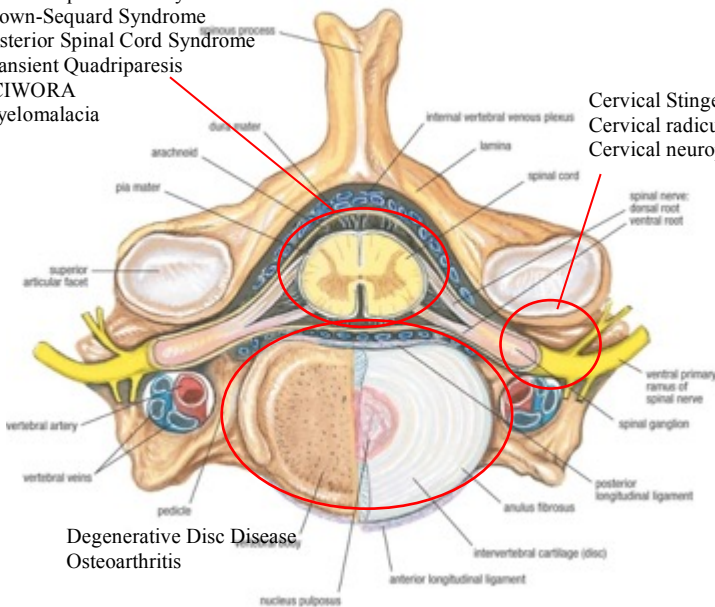
Cervical Spine Injuries



Hyperflexion sprain (ligaments not shown)

- Transverse Myelopathy
- Central Cord Syndrome
- Anterior Spinal Cord Syndrome
- Brown-Sequard Syndrome
- Posterior Spinal Cord Syndrome
- Transient Quadriplegia
- SCIWORA
- Myelomalacia

- Cervical Stingers
- Cervical radiculopathies
- Cervical neuropathies



Degenerative Disc Disease, Osteoarthritis

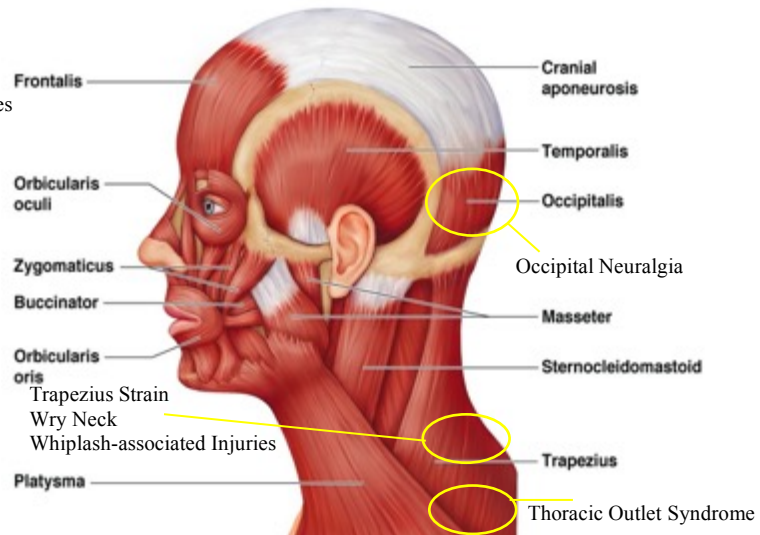


Image retrieved from: <http://libcat.org/gross-anatomy-of-the-skeletal-muscles-muscles-of-the-head>

Sports & Exercise Medicine Differential Guidebook©
Dr. A Francella, Dr N Dilworth 2020/21©

Image retrieved from: <https://humananatomyly.com/cross-section-of-the-spine/cross-section-of-the-spine-cross-section-of-human-vertebrae-spine-cross-section-anatomy-spine/>

Sports & Exercise Medicine Differential Guidebook©
Dr. A Francella, Dr N Dilworth 2020/21©

Injury: Fractures	# of cases seen	Age/Gender	Sport Type	INVESTIGATION
C1 – Jefferson				Immobilize Cspine – ER – CT Cspine
C2: Hangman’s Ondontoid				Immobilize Cspine – ER – CT Cspine
C3-C7 Burst Wedge				Immobilize Cspine – ER – CT Cspine
C6-T1 Clay Shoveler				Immobilize Cspine – ER – CT Cspine
Pillar fracture				Immobilize Cspine – ER – CT Cspine
Pedicolaminar fracture- separation				Immobilize Cspine – ER – CT Cspine
Teardrop fracture				Immobilize Cspine – ER – CT Cspine
Laminar fracture				Immobilize Cspine – ER – CT Cspine
Bilateral facet fracture/dislocation				Immobilize Cspine – ER – CT Cspine
Spinal Cord				
Transverse Myelopathy				MRI cspine
Central Cord Syndrome				MRI cspine
Anterior Spinal Cord Syndrome				MRI cspine
Brown-Sequard Syndrome				MRI cspine
Posterior Spinal Cord Syndrome				MRI cspine
Transient Quadripareisis				MRI cspine
C-Spine				
Cervical Stingers				Xray Cspine, CT Cspine, MRI Cspine, MRI neurography – Brachial plexus
Spinal cord injury without radiographic abnormalities (SCIWORA)				MRI Cspine/Tspine/Lspine as indicated

Shoulder Injuries

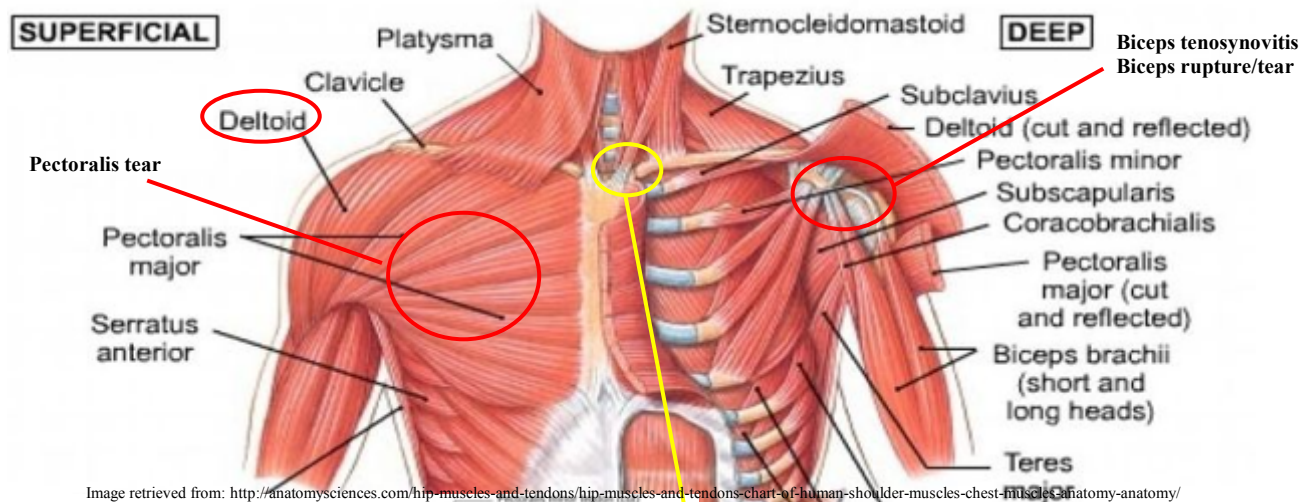
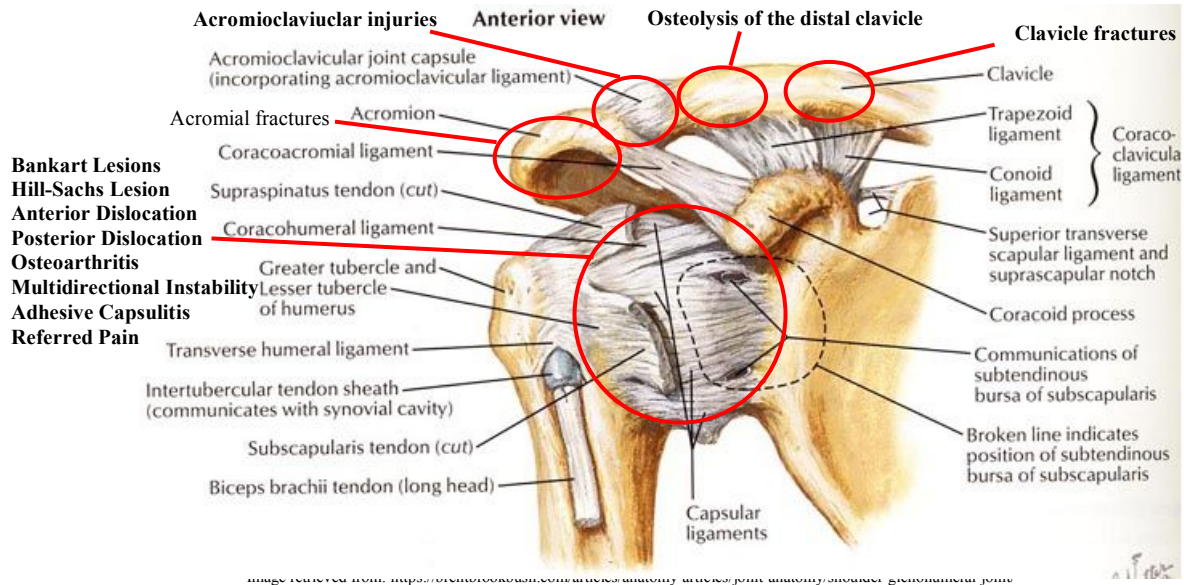
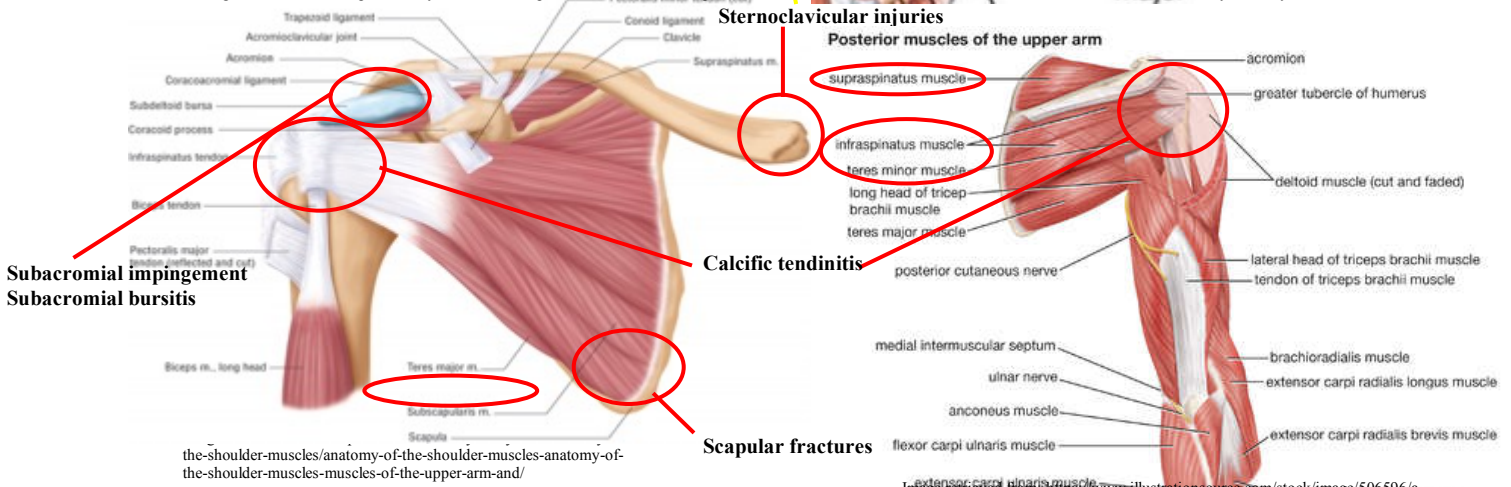


Image retrieved from: <http://anatomysciences.com/hip-muscles-and-tendons/hip-muscles-and-tendons-chart-of-human-shoulder-muscles-chest-muscles-anatomy-anatomy/>



the-shoulder-muscles/anatomy-of-the-shoulder-muscles-anatomy-of-the-shoulder-muscles-muscles-of-the-upper-arm-and/

Image retrieved from: https://www.illustrationsource.com/stock/image/506596/a-posterior-view-of-the-muscles-of-the-human-upper-arm/?&results_per_page=1&detail=TRUE&page=2

Injury: Tendon/Muscle	# of cases seen	Age/Gender	Sport Type	INVESTIGATION
Supraspinatus				US shoulder, MRI shoulder
Infraspinatus				US shoulder, MRI shoulder
Teres Minor				US shoulder, MRI shoulder
Subscapularis				US shoulder, MRI shoulder
Deltoid				US shoulder, MRI shoulder
Biceps tenosynovitis				US shoulder, MRI shoulder
Biceps rupture/tear				US shoulder, MRI shoulder
Pectoralis tear				US shoulder, MRI MSK Chest
Bone/Ligaments				
Acromioclavicular injuries				Xray AC, CT shoulder, MRI Shoulder
Clavicle fractures				Xray clavicle, CT clavicle
Scapular fractures				Xray scapular views, CT scapula
Acromial fractures				Xray shoulder, CT shoulder, MRI shoulder
Bankart lesions				Xray Shoulder, MRI shoulder, CT shoulder, MRA shoulder
Hill-Sachs lesions				Xray Shoulder, MRI shoulder, CT shoulder, MRA shoulder
Anterior dislocation				Xray Shoulder, MRI shoulder, CT shoulder, MRA shoulder
Posterior dislocation				Xray Shoulder, MRI shoulder, CT shoulder, MRA shoulder
Sternoclavicular injuries				CT chest (if concern for post.) MRI MSK Chest
Osteoarthritis				Xray shoulder
Other				
Multidirectional instability				Xray shoulder, MRI shoulder
Calcific Tendinitis				Xray shoulder, US shoulder

Sports & Exercise Medicine Differential Guidebook©

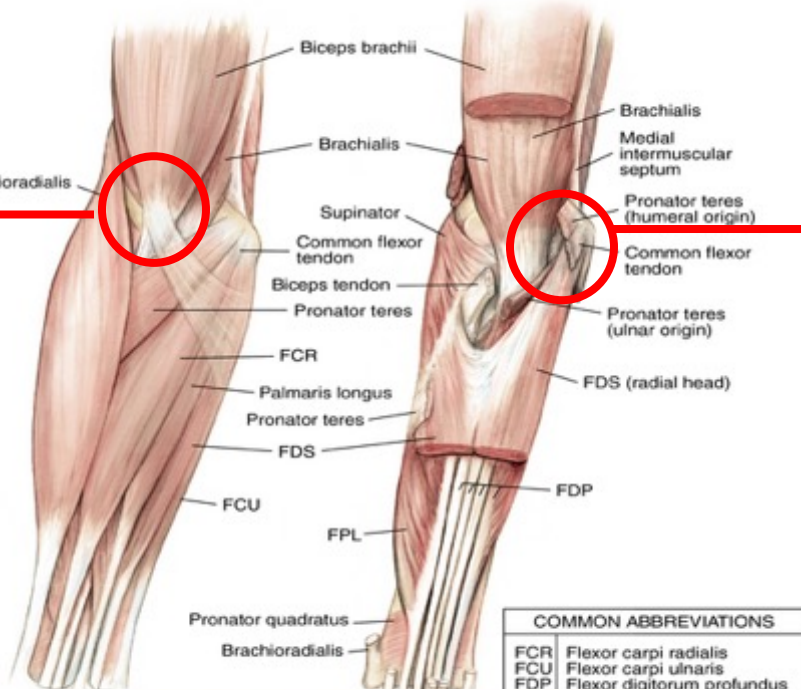
Dr. A Francella, Dr N Dilworth 2020/21©

Adhesive Capsulitis				R/O other causes: Xray shoulder, MRI shoulder, US shoulder (may see thickening of coracohumeral ligament)
Osteolysis of distal clavicle				Xray AC, CT shoulder
Subacromial Impingement				US shoulder
Subacromial bursitis				US shoulder
Suprascapular nerve impingement				MRI Shoulder
SLAP and Labraltears				MRI shoulder, MRA shoulder
Referred Pain				

Elbow Injuries

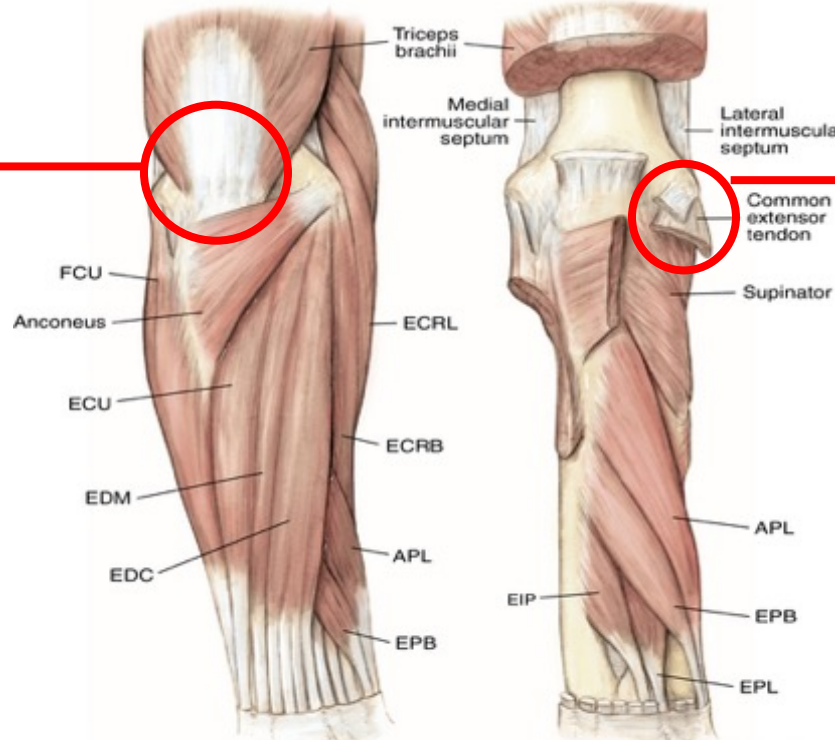
Muscles and Tendons

Distal Biceps Tendinitis
Distal Biceps Tear



Medial Epicondylitis

Triceps Tear
Snapping Triceps



Lateral Epicondylitis

COMMON ABBREVIATIONS			
APL	Abductor pollicis longus	EDM	Extensor digiti minimi
ECRB	Extensor carpi radialis brevis	EIP	Extensor indicis profundus
ECRL	Extensor carpi radialis longus	EPB	Extensor pollicis brevis
EDC	Extensor digitorum communis	EPL	Extensor pollicis longus

B

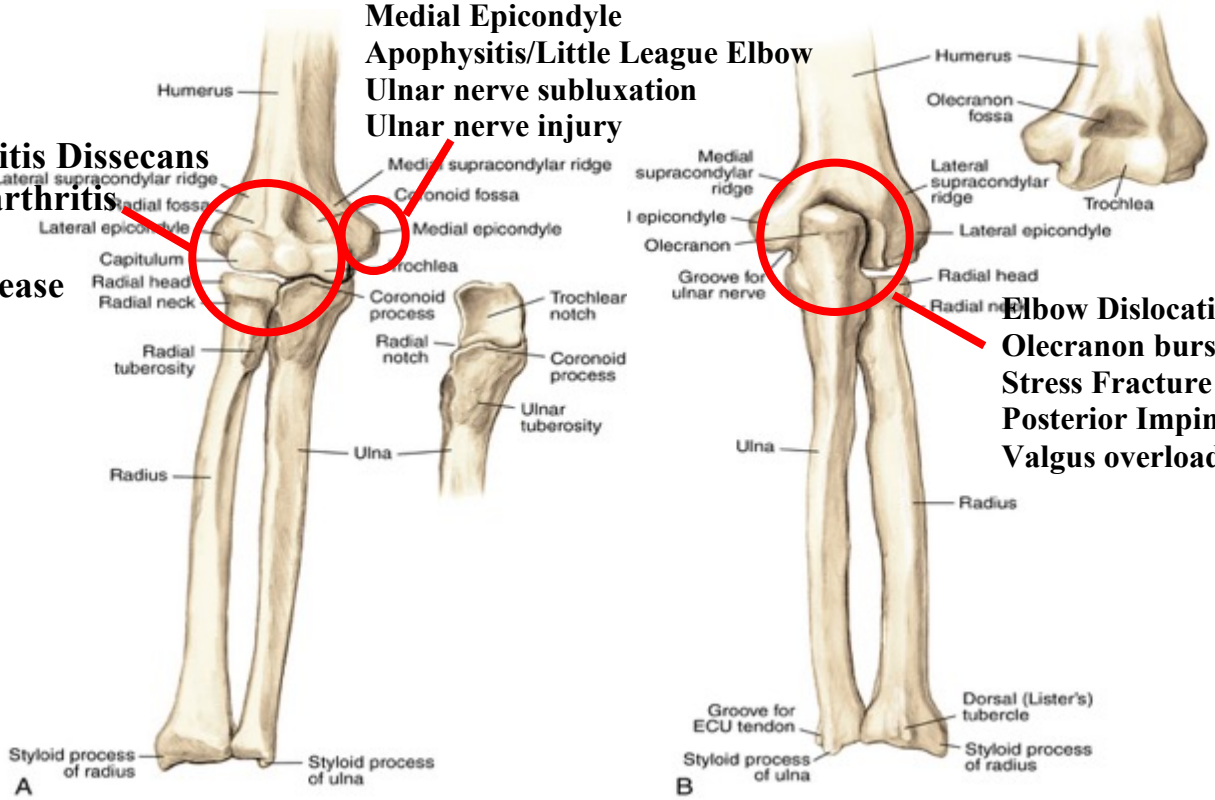
Sports & Exercise Medicine Differential Guidebook©
 Dr. A Francella, Dr N Dilworth 2020/21©

Injury	# of cases seen	Age/Gender	Sport Type	INVESTIGATION
Lateral Epicondylitis				US elbow, Xray elbow
Medial Epicondylitis				US elbow, Xray elbow
Distal Biceps Tendinitis				US elbow, Xray elbow
Distal Biceps Tear				US elbow, Xray elbow
Triceps Tear				US elbow, Xray elbow
Snapping Triceps Syndrome				Dynamic US elbow
Other				
Loose bodies				Xray elbow, MRI elbow

Bones, Ligaments, and Other Injuries

Osteochondritis Dissecans
Elbow osteoarthritis
Fractures
Panner's Disease

Medial Epicondyle
Apophysitis/Little League Elbow
Ulnar nerve subluxation
Ulnar nerve injury

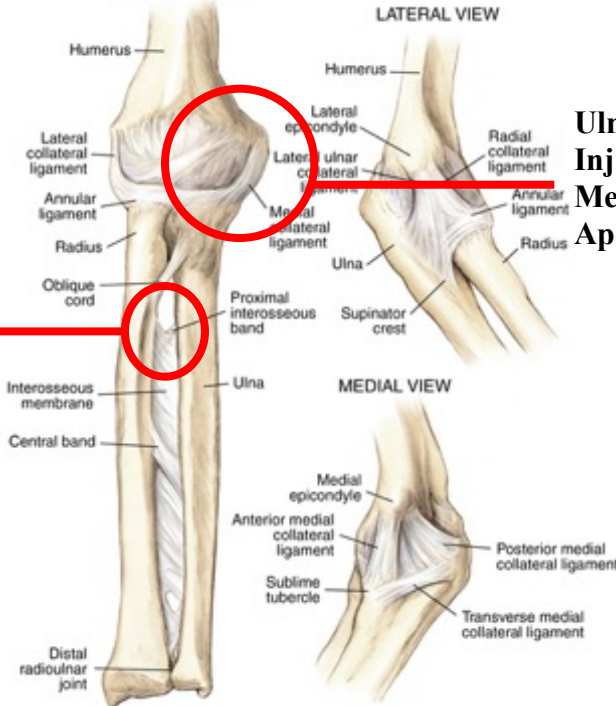


Elbow Dislocation
Olecranon bursitis
Stress Fracture
Posterior Impingement/
Valgus overload

Radial Tunnel Syndrome

ANTERIOR VIEW

LATERAL VIEW



Ulnar Collateral Ligament
Injuries
Medial Epicondylitis
Apophysitis/Little League Elbow

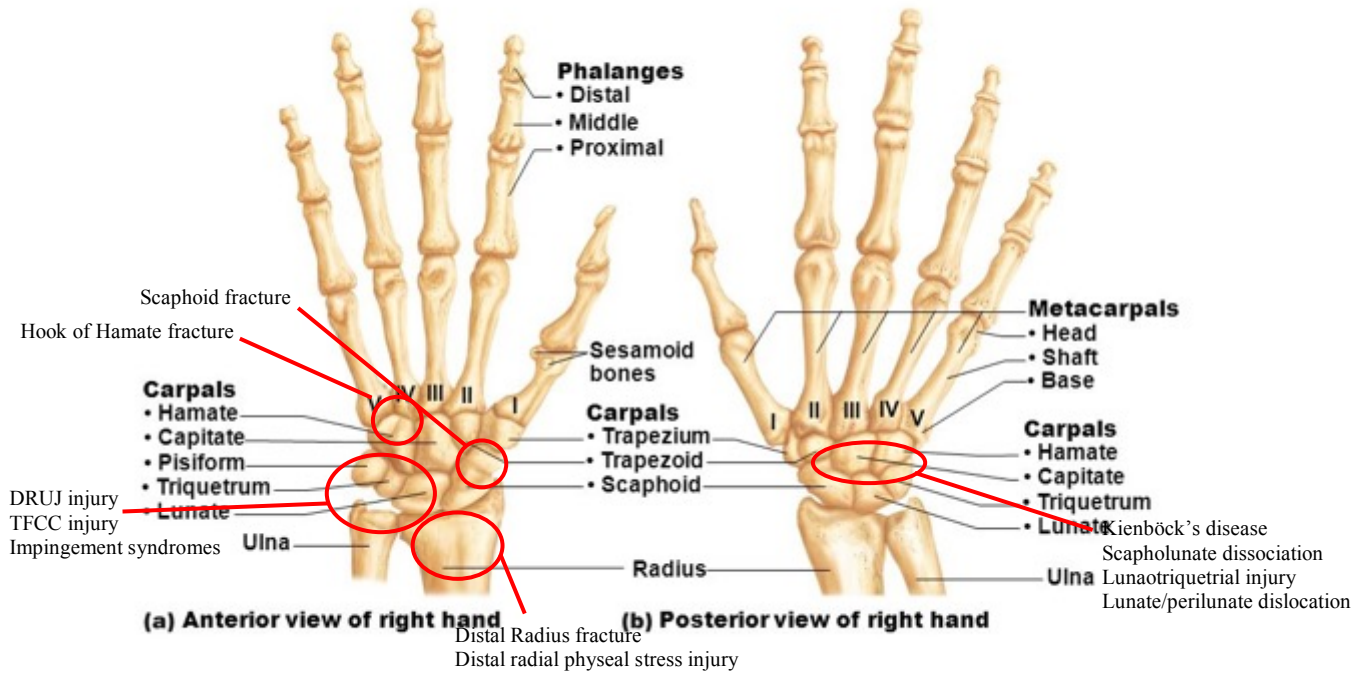
Sports & Exercise Medicine Differential Guidebook©

Dr. A Francella, Dr N Dilworth 2020/21©

Bone/Ligament	# of cases seen	Age/Gender	Sport Type	INVESTIGATION
Osteochondritis Dissecans				Xray elbow, MRI elbow, MRA elbow, CT elbow
Medial Epicondyle Apophysitis/Little League Elbow				Xray elbow, MRI elbow
Ulnar Collateral Ligament Injuries				Xray elbow (valgus stress), MRI elbow, MRA elbow
Elbow Dislocations				Xray elbow, MRI elbow
Posterior Impingement/ Valgus overload				Xray Elbow
Elbow osteoarthritis				Xray Elbow
Ulnar nerve subluxation				Dynamic US elbow
Ulnar nerve injury				EMG, NCS, MRI neurography
Radial Tunnel Syndrome/Posterior Interosseous Nerve Entrapment				R/O other (US elbow, MRI elbow, NCS, EMG – all may be normal)
Olecranon Bursitis				US elbow, consider aspiration C+S, crystallography
Stress fractures				Xray elbow, MRI elbow, CT elbow
Panner's Disease				Xray elbow, MRI elbow
Fractures				Xray elbow
Synovial Plica				MRI elbow
Radial collateral ligament injury				MRI elbow, MRA elbow
OTHER				

Wrist Injuries

Figure 7.29 Bones of the right hand.



© 2013 Pearson Education, Inc.

Image retrieved from: http://www.thepinista.com/skeleton-hand-dorsal-view_0101R1d4bmD57X2DD8evLFpx84TSQ7mL%7C5HL3SqYs8/

Figure 11.11d Intrinsic Muscles, Tendons, and Ligaments of the Hand

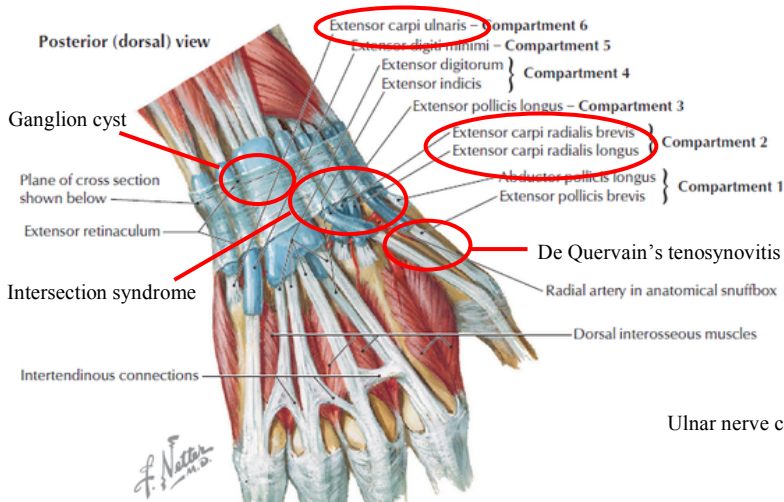
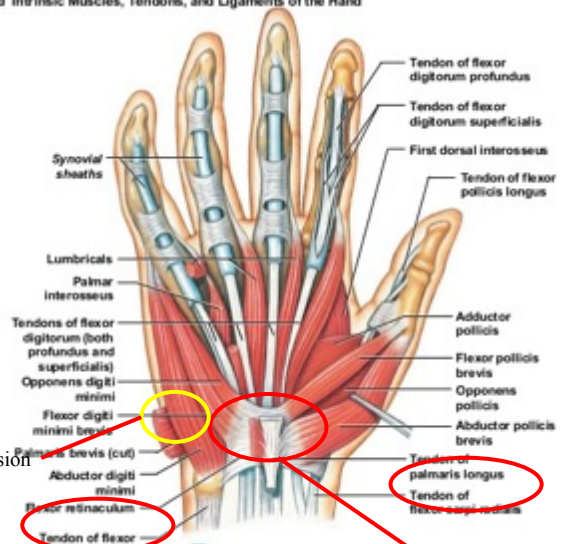


Image retrieved from: <https://sites.google.com/site/3r03msklearningportfolio/?tmpl=%2Fsystem%2Fapp%2Ftemplates%2Fprint%2F&showPrintDialog=1>



© 2013 Pearson Education, Inc.

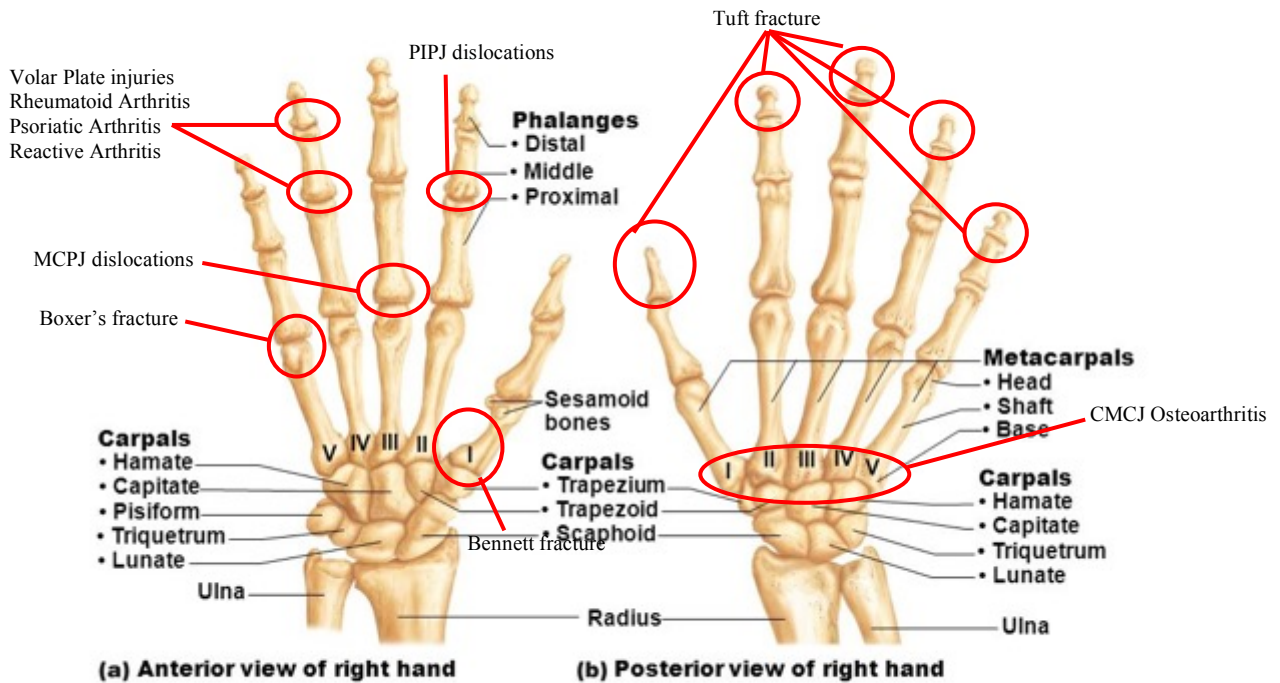
Image retrieved from: <https://www.pinterest.ca/pin/204069426844687303/?lp=true>

Carpal Tunnel syndrome

Injury:	# of cases	Age/Gender	Sport Type	INVESTIGATION
Bone	seen			
Distal radius fracture				Xray Wrist
Scaphoid fracture				Xray Wrist, scaphoid views
Hook of Hamate fracture				Xray wrist, hamate views
Kienböck's disease				Xray wrist
Distal radial physeal stress injury				Xray Wrist, MRI wrist
Impingement syndromes				
Ligament/Cartilage				
Scapholunate injury				Xray wrist, scaphoid views (including closed fist)
Lunotriquetral injury				Xray wrist
Lunate/perilunate dislocation				Xray wrist
Distal Radioulnar joint (DRUJ) instability				Xray Wrist, MRI wrist
Triangular Fibrocartilage complex (TFCC) injury				US wrist, xray wrist, MRI wrist
Tendon				
DeQuervain's tenosynovitis				US wrist
Intersection syndrome				US wrist
Extensor/Flexor Carpi Ulnaris tendinopathy/Snapping				US wrist, Dynamic US wrist
Flexor Carpi radialis tendinopathy				US wrist
Nerve				
Carpal tunnel syndrome				EMG, NCS
Ulnar nerve compression				EMG, NCS
Other				
Ganglion Cyst				US wrist
Dislocation of CMC				Xray wrist

Hand Injuries

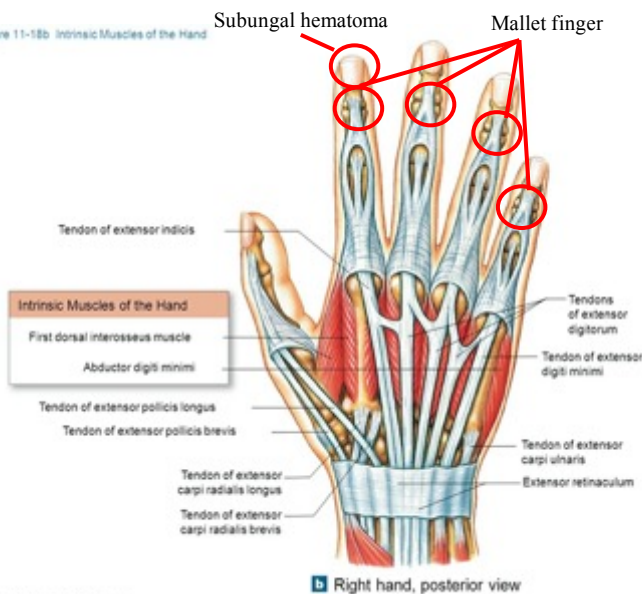
Figure 7.29 Bones of the right hand.



© 2013 Pearson Education, Inc.

Image retrieved from: http://www.thepinsta.com/skeleton-hand-dorsal-view_0IO1R1d4bmD57X2DD8cvLFpx84TSQ7mL%7C5HL3SqYs8/

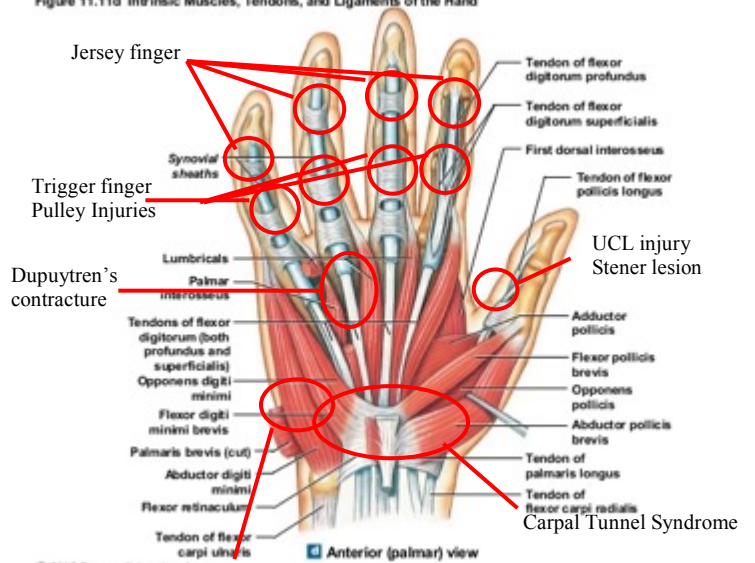
Figure 11-18b Intrinsic Muscles of the Hand



© 2012 Pearson Education, Inc.

Image retrieved from: <https://humananatomychart.com/hand-muscle-anatomy/hand-muscle-anatomy-right-hand-muscles-anatomy-human-anatomy-labelled/>

Figure 11.11d Intrinsic Muscles, Tendons, and Ligaments of the Hand



© 2012 Pearson Education, Inc.

Guyon's Canal

Syndrome Image retrieved from: <https://www.pinterest.ca/pin/204069426844687303/?lp=true>

Injury: Tendon/Muscle/Ligament	# of cases seen	Age/Gender	Sport Type	INVESTIGATION
Jersey Finger				Xray finger
Mallet Finger				Xray finger
Trigger Finger				US finger
Pulley Injuries				US finger
Ulnar Collateral Ligament injuries				US D1/Thumb
Stener Lesion				US D1, xray D1
Bone/Joint				
Bennett Fracture				Xray hand
Boxer's Fracture				Xray Hand
Tuft Fracture				Xray finger
Volar Plate injuries				Xray finger
PIPJ dislocations				Xray finger
MCPJ dislocations				Xray hand
CMCJ Osteoarthritis				Xray hand
Other				
Dupuytren's contracture				US hand
Carpal Tunnel Syndrome				NCS/EMG
Guyon's Canal Syndrome				NCS/EMG
Rheumatoid Arthritis				Xray/US wrist/hand, arthrocentesis, Inflammatory bloodwork
Psoriatic Arthritis				Xray/US wrist/hand, arthrocentesis, Inflammatory bloodwork
Reactive Arthritis				Xray/US wrist/hand, arthrocentesis, Inflammatory bloodwork
Subungal Hematoma				Xray finger
Acute Compartment Syndrome				Compartment testing
Chronic Regional Pain Syndrome				Xray wrist/hand
Referred Pain				

Injury: Child/Adolescent	# of cases seen	Age/Gender	Sport Type	INVESTIGATION
Scoliosis				Xray scoliosis survey
Spondylolitis				Xray Lspine, MRI Lspine
Spondylolisthesis				Xray Lspine, MRI Lspine, CT Lspine
Scheuermann's Kyphosis				Xray Tspine, MRI Tspine
Discitis				MRI spine (area of concern), Blood cultures, and Infectious workup
Adult				
Mechanical Low Back Pain <ul style="list-style-type: none"> - Pattern 1a Flexion type - Pattern 1b Flexion type - Pattern 2 Extension - Pattern 3 Leg-dominant constant - Pattern 4 Leg dominant intermittent 				Atraumatic, < 3 months, no red flag/neurological sx - no imaging required
Lumbar Disc Herniation/Radiculopathy				MRI Lumbar spine
Cauda Equina Syndrome				MRI Spine
Inflammatory Spondyloarthropathy				MRI Spine and sacroiliac joints
Older Adult				
Lumbar Spinal Stenosis				MRI lumbar spine
Osteoporotic Compression Fractures				Xray Tspine/Lspine
Metastatic Spine disease				Xray Thoracolumbar spine, Bone scan, MRI spine
Adult Degenerative Spinal Deformity				Xray Spine, MRI spine
Other				
Sacroiliac Dysfunction				
Transverse Process fracture				Xray Lspine, MRI Lspine
Schmorl's nodes				MRI Lspine

Sports & Exercise Medicine Differential Guidebook©
Dr. A Francella, Dr N Dilworth 2020/21©

Image retrieved from: <https://humanatomyly.com/leg-knee-muscles-diagram/leg-knee-muscles-diagram-25-best-ideas-about-knee-joint-anatomy-on-pinterest-anatomy-of/>

Sports & Exercise Medicine Differential Guidebook©
Dr. A Francella, Dr N Dilworth 2020/21©

Injury: Anterior Pain	# of cases seen	Age/Gender	Sport Type	INVESTIGATION
Hip osteoarthritis				Xray Pelvis and Hip (AP pelvis, affected hip)
Femoroacetabular Impingement syndrome				Xray Pelvis and Hips (incl.Dunn's views)
Avascular necrosis				Xray Pelvis and Hip
Femoral neck stress fracture				Xray Femur, CT femur, MRI femur
Labral tear				MRI/MRA hip
Osteitis pubis				MRI groin pain protocol
Hip flexor/adductor tendinopathy				US hip
Inguinal related groin pain (Sport hernia/Athletic pubalgia)*abdo wall nerve impingements				MRI groin pain protol, US abdo (R/O hernia), Diagnostic nerve blocks
Lateral Pain				
Greater Trochanter Pain Syndrome (IT band, glutes, bursa, etc)				US greater trochanter, MRI hip
Lateral Femoral Cutaneous Nerve (LFCN) entrapment				Diagnostic LFCN injection
Lumbar radiculopathy				MRI Lspine
Posterior Pain				
Gluteal tendinopathy				US gluts/hip
Referred back pain: referral L5, SI joint				MRI Lspine
Hamstring tendinopathy				US hamstring
Hip osteoarthritis				Xray Pelvis and hip
Piriformis syndrome				MRI hip
Sacroiliac impingement				

Ischiofemoral impingement				MRI hip
Pediatric				
Slipped capital femoral epiphysis (SCFE)				Xray Pelvis, hip (include frog leg views)
Legg-Calvé-Perthes				Xray Pelvis and hip
Pelvic avulsion fractures				
- ASIS				Xray Pelvis
- AIIS				Xray Pelvis
- Iliac crest				Xray Pelvis
- Ischeal Ramus				Xray Pelvis
- Pubic tubercle				Xray Pelvis
- Lesser trochanter				Xray Pelvis/hip

Knee Injuries

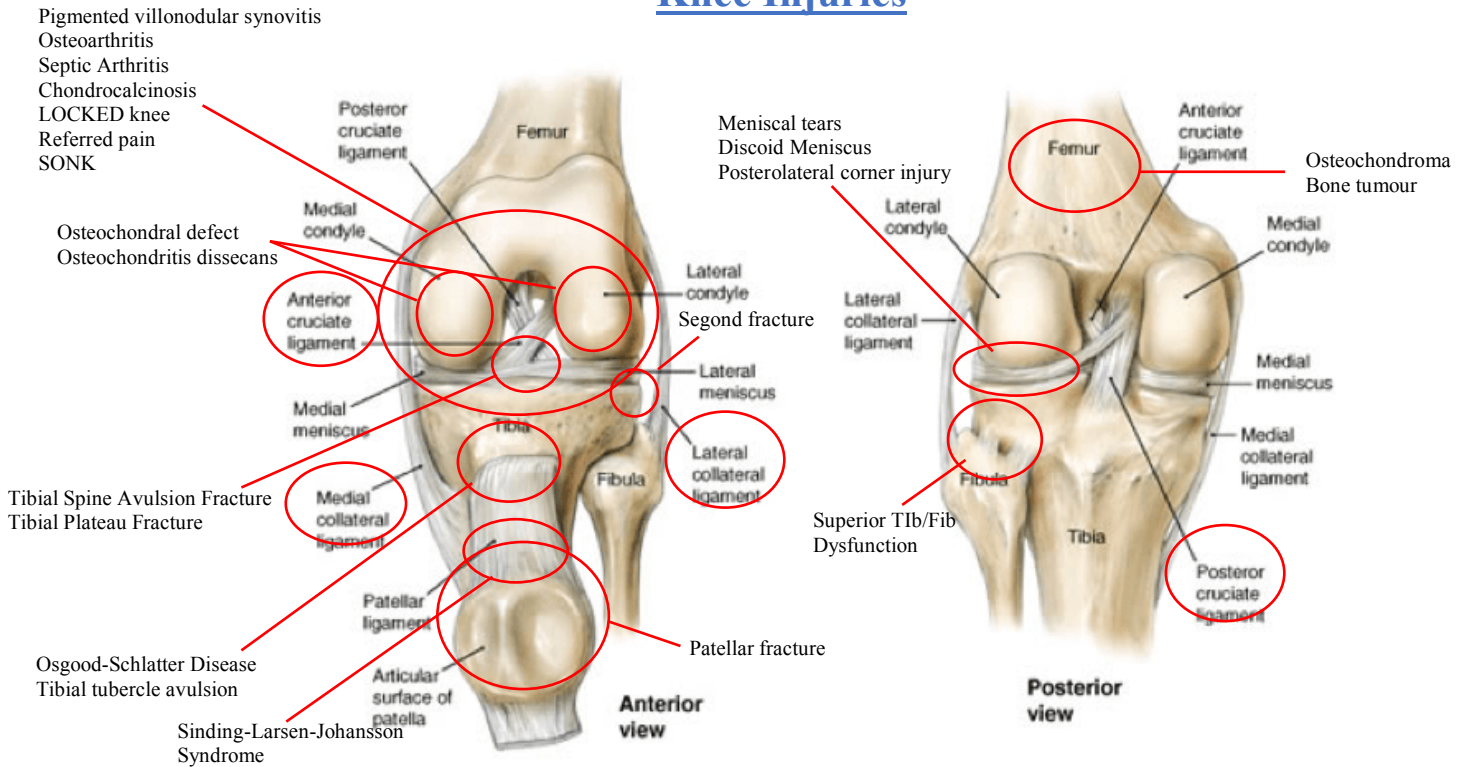


image retrieved from: <http://www.days-eye.com/nip-anatomy-muscles/aorabile-oranen-nip-anatomy-biology-concerned-study-shocking-discipline-nice-ideas-handmade-wonderful/>

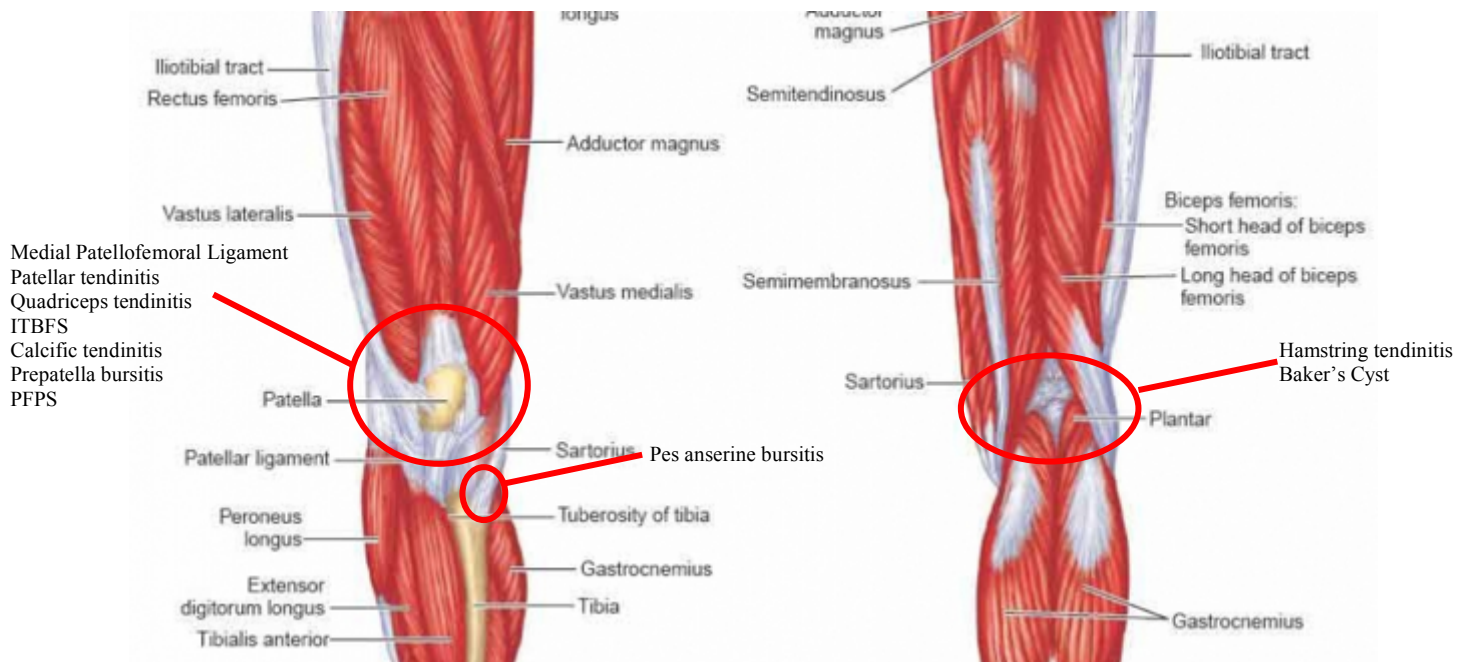


Image retrieved from: <https://humananatomyly.com/leg-knee-muscles-diagram/leg-knee-muscles-diagram-25-best-ideas-about-knee-joint-anatomy-on-pinterest-anatomy-of/>

Injury: Bone/Joint	# of cases seen	Age/Gender	Sport Type	INVESTIGATION
Osteochondral defect				Xray knees (B/L) (AP, Lat, Skyline, tunnel, WB), MRI knee, MRA knee
Osteochondritis dissecans				Xray knees (B/L) (AP, Lat, Skyline, tunnel, WB), MRI knee, MRA knee
Pigmented villonodular synovitis				MRI knee
Meniscal tears				MRI knee
Discoid Meniscus				MRI knee
Segond fracture				Xray Knee +/- MRI knee
Tibial spine avulsion fracture				Xray knee +/- MRI knee
Tibial plateau fracture				Xray knee, CT knee, MRI knee
Patellar fracture				Xray knee, CT knee
PFPS – alignment, overuse, instability, trauma, chondral defect				Xray knee, MRI knee
Osteoarthritis – unicompartmental, bicompartamental, tricompartmental				Xray knees (AP, Lat, Skyline, tunnel, WB)
Superior Tib/Fib Dysfunction				
Ligament				
Anterior Cruciate Ligament				MRI knee
Posterior Cruciate Ligament				MRI knee
Medial Collateral Ligament				US knee, MRI knee
Lateral Collateral Ligament				US knee, MRI knee
Medial Patellofemoral Ligament (MPFL)				MRI knee
Anterolateral Ligament (ALL)				MRI knee

Sports & Exercise Medicine Differential Guidebook©

Dr. A Francella, Dr N Dilworth 2020/21©

Posterolateral corner injury				MRI knee
Musculotendinous				
Patellar tendinitis				US knee
Quadriceps tendinitis				US knee
ITBFS				MRI knee
Hamstring tendinitis				US knee
Pes anserine bursitis				US knee
Calcific tendinitis – Quad/Patella				US knee, xray Knee
Popliteus Strain				MRI knee
Pediatric/Other				
Osgood-Schlatter Disease				Xray knee
Tibial tubercle avulsion				Xray knee
Spontaneous Osteonecrosis of the knee (SONK)/Insufficiency fracture)				Xray knees, MRI knees, CT knee
Osteochondroma				Xray knee
Bone tumours				Xray knee, MRI knee, CT knee, bone scan
Bursitis – suprapatellar, prepatellar, infrapatellar (ant/post.)				US knee
Septic Arthritis				Arthrocentesis, Xray knee
Chondrocalcinosis				Xray knee +- arthrocentesis
LOCKED knee – ACL, loose body, bucket handle meniscal tear, node synovitis, chondroma, ganglion cyst				Xray knee, MRI knee
Referred pain – radiculopathy, hip, OA, SCFE/SUFE				
Baker’s Cyst				

Hoffa fat pad impingement				MRI knee if chronic
Snapping Conditions – Semitendinosus, Biceps Femoris, ITB				
Hoffa fat pad chondroma				MRI knee, xray knee
Synovitis nodes				Xray knee, MRI knee

Ankle Injuries

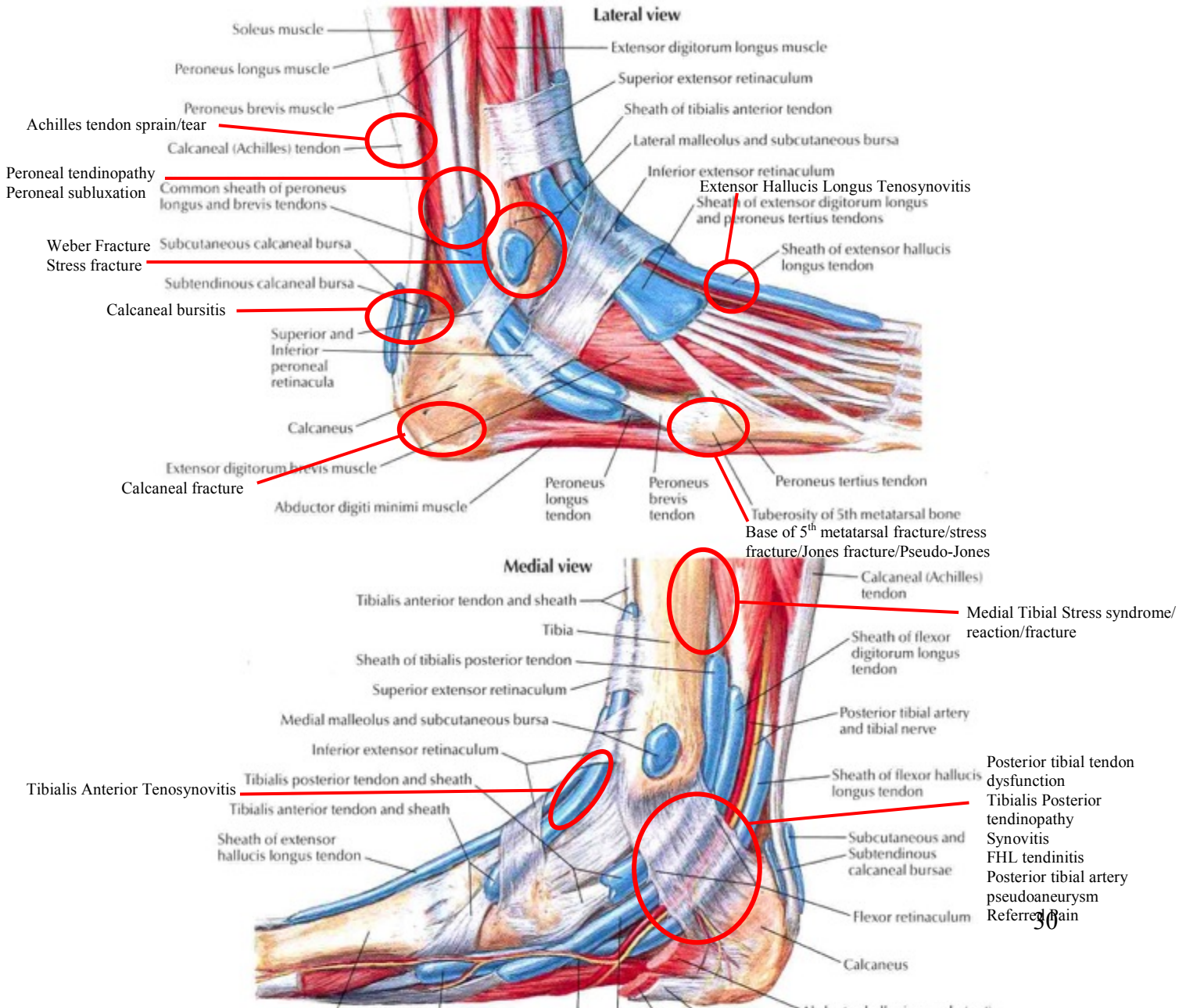
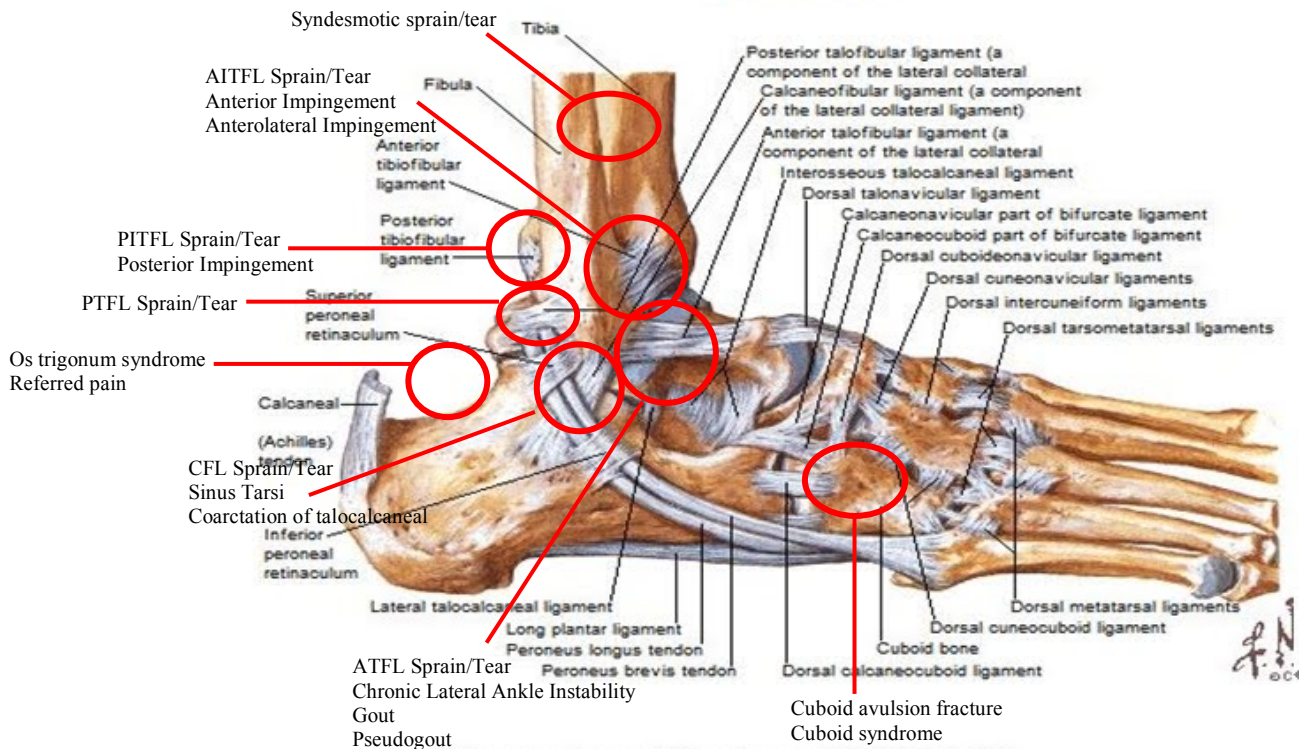


Image retrieved from: <https://humananatomychart.com/anatomy-of-the-foot-ligaments-and-tendons/anatomy-of-the-foot-ligaments-and-tendons-foot-anatomy-tendons-ankle-anatomy-ligaments-and-tendons-ankle/>

Ligaments and Tendons of Right Ankle Lateral View



Ligaments and Tendons of Right Ankle Medial View



Sports & Exercise Medicine Differential Guidebook©
Dr. A Francella, Dr N Dilworth 2020/21©

Injury: Anterior	# of cases seen	Age/Gender	Sport Type	INVESTIGATION
Anterior talofibular ligament (ATFL) sprain or tear				US ankle
Tibialis anterior tenosynovitis (skate bite)				US ankle
Extensor Hallucis tenosynovitis (skate bite)				US ankle/foot
Anterior inferior tibiofibular ligament (AITFL) sprain or tear				Xray ankle with stress views, MRI ankle
Anterior impingement				Xray ankle
Talar dome fracture				Xray ankle, CT ankle, MRI ankle
Osteochondral defect/ Osteochondritis dissecans				Xray ankle, CT ankle, MRI ankle
Lateral				
ATFL sprain or tear				US ankle
Chronic lateral ankle instability				MRI ankle
Anterolateral impingement syndrome				Xray ankle
Posterior impingement syndrome				Xray ankle
Weber fractures				Xray ankle
Fibular stress fracture				Xray tibia/fibula, MRI tibia/fibula, CT tibia/fibula
Talar dome fracture				Xray ankle, CT ankle, MRI ankle
Osteochondral defect/ Osteochondritis dissecans				Xray ankle, CT ankle, MRI ankle
Peroneal tendinopathy				US ankle
Peroneal subluxation				Dynamic US ankle
Calcaneofibular ligament (CFL) sprain/tear				Ankle US
Sinus tarsi				
Cuboid syndrome				

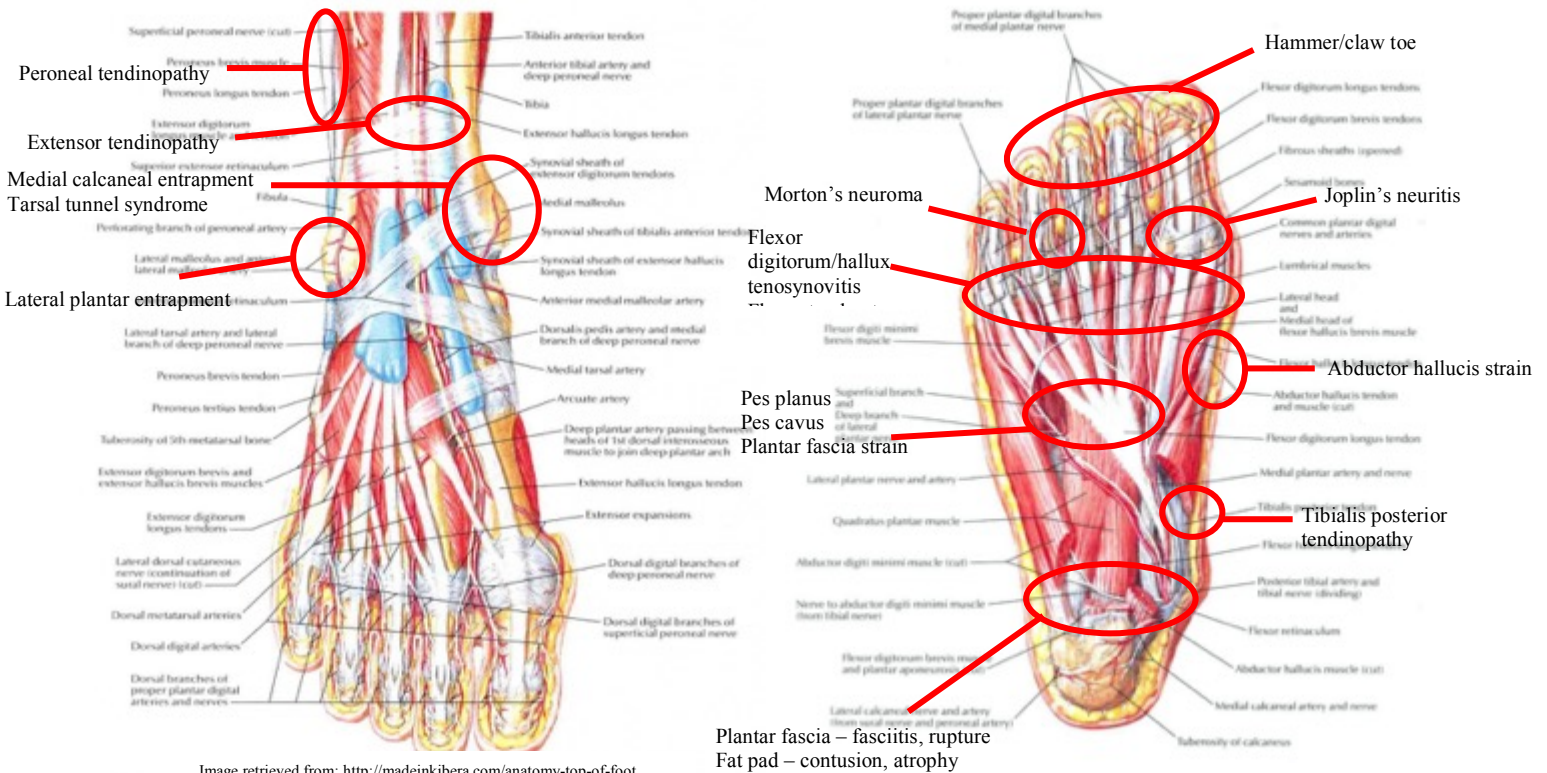
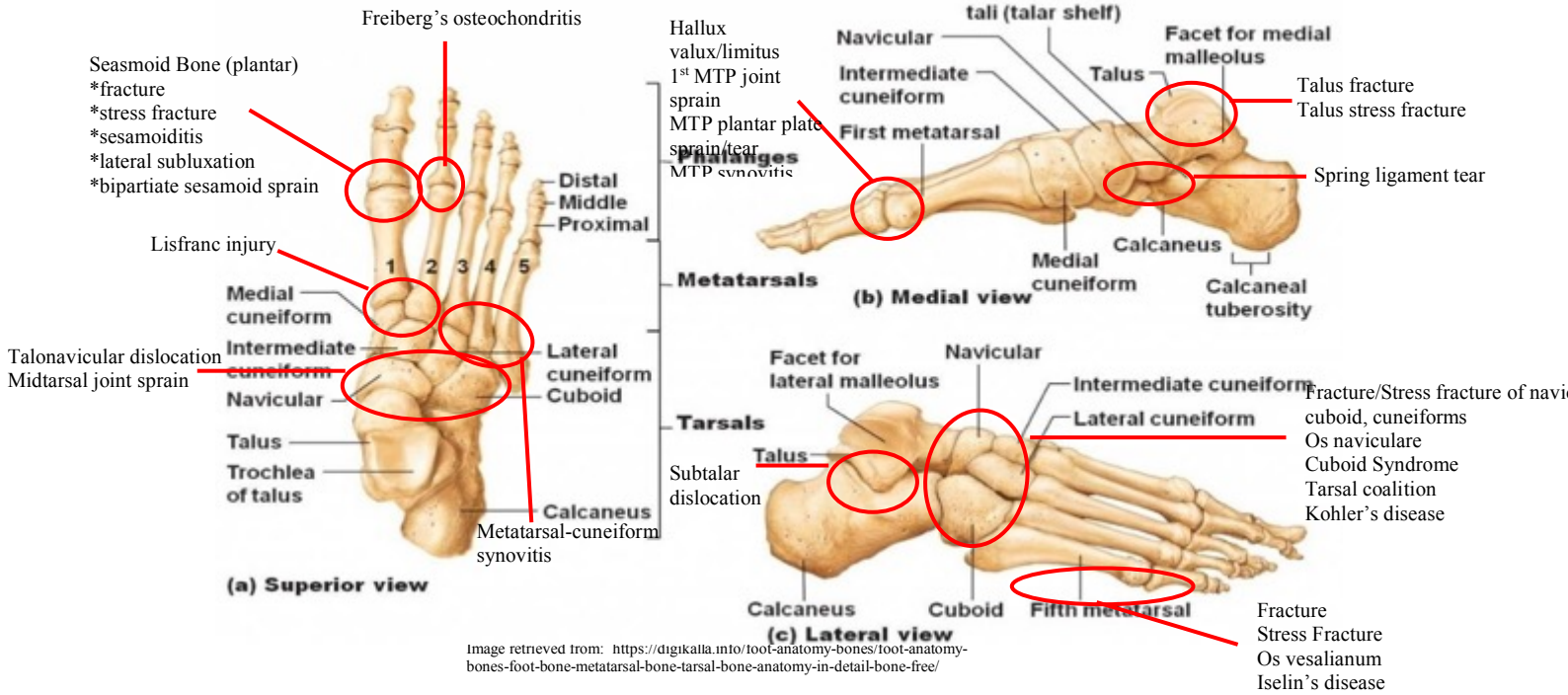
Cuboid avulsion fracture				Xray foot
Base of the 5 th metatarsal fractures (acute fracture/Stress fracture/Jones fracture/pseudo-Jones fracture)				Xray foot
Referred pain from lumbar spine, peroneal nerve, or STFJ				
Medial				
Deltoid sprain/tear				US ankle
Tibialis Posterior tendinopathy				US ankle
Posterior tibial tendon dysfunction				US ankle
Spring ligament sprain/tear				MRI foot
Synovitis, joint effusion				
Medial tibial traction syndrome/stress reaction/fracture				Exertional compartment testing, Bone scan, MRI tibia/fibula
Navicular fracture				Xray foot, MRI foot
Mueller Weiss Syndrome				Xray foot, CT foot, MRI foot
Os Naviculare synchondrosis				Xray foot (incl. bilateral AP WB views of feet)
Flexor Hallucis longus tendinopathy				US foot
Posterior tibial artery pseudoaneurysm				US ankle, CTA
Referred pain from lumbar spine				
Posterior				
Achilles tendinopathy/tear				US ankle
Os trigonum syndrome				Xray ankle
Posterior inferior tibiofibular ligament (PITFL) sprain or tear				Xray ankle (incl. stress views) MRI ankle
Posterior talofibular ligament (PTFL) sprain or tear				
Pilon/Plafond fracture				Xray ankle, CT ankle

Sports & Exercise Medicine Differential Guidebook©

Dr. A Francella, Dr N Dilworth 2020/21©

Posterior impingement				Xray ankle
Calcaneal bursitis				US heel/achilles
Calcaneal fracture				Xray calcaneus, CT calcaneus
Other				
Syndesmotic sprain/tear				Xray ankle (incl. stress views)
Coarctation of talocalcaneal				Xray ankle, CT ankle, MRI ankle
Coarctation of calcaneonavicular				Xray ankle, CT ankle, MRI ankle
Gout				Xray area, arthrocentesis for crystallography
Pseudogout				Xray area, arthrocentesis for crystallography
Complex regional pain syndrome				Xray area

Foot Injuries



Injury: Hindfoot	# of cases seen	Age/Gender	Sport Type	INVESTIGATION
Bone - Fracture: talus, calcaneus - Stress #: talus, calcaneus				Xray calcaneus, CT calcaneus, Xray ankle, CT ankle
Joint - Subtalar dislocation - Midtarsal joint sprain - Spring ligament tear - Talonavicular dislocation				Subtalar – Xray ankle, CT ankle Spring ligament -MRI foot Talonavicular dislocation – Xray foot, CT foot
Other - Plantar fascia – fasciitis, rupture - Plantar fibroma - Fat pad – contusion, atrophy				Fasciitis – US foot Fibroma – US foot, MRI foot
Nerve - medial calcaneal entrapment - lateral plantar entrapment - tarsal tunnel syndrome				
Midfoot				
Bone - Fracture – cuboid, navicular - Stress # - navicular, cuboid, cuneiform - Os naviculare - Cuboid syndrome - Tarsal coalition - Kohler’s disease				Xray foot, CT foot
Joint - Lisfranc injury (sprain, fracture, dislocation)				Xray foot, CT foot, MRI foot
Tendon - Extensor tendinopathy (ie. Tibialis anterior) - Tibialis posterior tendinopathy - Peroneal tendinopathy - Abductor hallucis strain				US foot
Other - Pes planus - Pes cavus - Plantar fascia strain				
Forefoot				

Sports & Exercise Medicine Differential Guidebook©

Dr. A Francella, Dr N Dilworth 2020/21©

Bone - Fracture – sesamoid, 5 th MT (styloid, metaphyseal-diaphyseal, shaft), 1 st -4 th MTs - Stress # - sesomid, MT shaft - 5 th MT – os vesalinum, Iselin’s disease - Sesamoid – sesamoiditis, lateral subluxation, bipartiate sesamoid sprain - Freiberg’s osteochondritis				Sesamoid injuries - Xray foot -sesamoid views, MRI foot
Joint - Hallux valgus/limitus - MTP/metatarsal-cuneiform synovitis (metatarsalgia) - 1 st MTP joint sprain (turf toe) - MTP plantar plate sprain/tear (floating toe syndrome)				Xray Foot D1- MRI foot D1
Tendon - Flexor digitorum/hallux tenosynovitis - Flexor tendon tear (a/w turf toe)				Xray Foot D1- MRI foot D1
Nerve - Morton’s neuroma - Joplin’s neuritis				Morton’s Neuroma - US foot
Skin				
Corns				
Calluses				
Plantar wart				
Subungal hematoma				
Onychomycosis				
Onychocryptosis				
Piezogenic Papules				
Other				
Referred pain				
Peripheral neuropathy				
Radiculopathy				
Complex regional pain syndrome				

Other Sport Medicine Topics

Altitude Related Illness	# of cases seen	Age/Gender	Sport Type	INVESTIGATION
Acute mountain sickness (AMS)				
High-altitude cerebral edema (HACE)				CT head
High-altitude pulmonary edema (HAPE)				Xray Chest
Bone Stress Injuries	# of cases seen	Age/Gender	Sport Type	INVESTIGATION
				Xray, Bone scan, CT area, MRI area
Cardiac	# of cases seen	Age/Gender	Sport Type	INVESTIGATION
Supraventricular Tachycardia				ECG, holter – cardiology
Short QT Syndrome				ECG, holter - cardiology
Long QT Syndrome				ECG, holter - cardiology
Brugada Syndrome				ECG, holter - cardiology
Hypertrophic Obstructive Cardiomyopathy (HOCM)				ECG, echocardiogram – cardiology
Arrhythmogenic Right Ventricular Dysplasia (ARVD)				ECG, echocardiogram, Cardiology
Catecholaminergic polymorphic ventricular tachycardia (CPVT)				ECG, holter, exercise stress test - cardiology
Wolff-Parkinson-White Syndrome (WPW)				ECG, holter - cardiology
Commotio Cardis				ECG, Holter, Echo - Cardiology
Concussion (Sport-Related)	# of cases seen	Age/Gender	Sport Type	INVESTIGATION
Persistent concussion				

Sports & Exercise Medicine Differential Guidebook©

Dr. A Francella, Dr N Dilworth 2020/21©

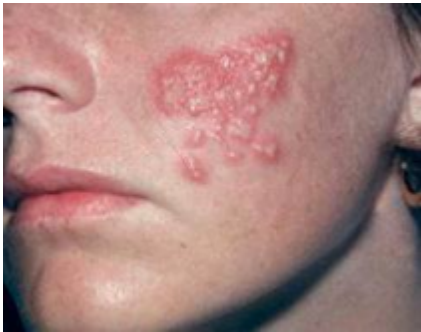Return to learn				
Return to play				
Return to work				
(8 concussion injury domains)				
Cervical injury				Xray flexion/extension views, CT Cspine
Vestibular dysfunction				
Visual dysfunction				
Sleep dysfunction				
Psychological dysfunction				
Post-traumatic headache				
Autonomic dysfunction				
Connective Tissue Disorders	# of cases seen	Age/Gender	Sport Type	INVESTIGATION
Marfan's Syndrome				CTD specialist
Ehlers-Danlos Syndrome				CTD specialist
	# of cases seen	Age/Gender	Sport Type	INVESTIGATION
Airway (eg. Anaphylaxis, trauma (facial, neck))				
Breathing (eg. Asthma, respiratory)				
Circulation (eg. shock, bleeding, cardiac pathology)				
Head injury				
C-spine injury				CT Cspine
Cerebrovascular accident				CT Head
Intracranial hemorrhage				CT Head
Seizure				
MSK Trauma				
Fracture				
Dislocation				
Amputation				
Neurovascular compromise				
Lightning Strikes				
Heat-related illnesses				
Heat exhaustion				

Sports & Exercise Medicine Differential Guidebook©

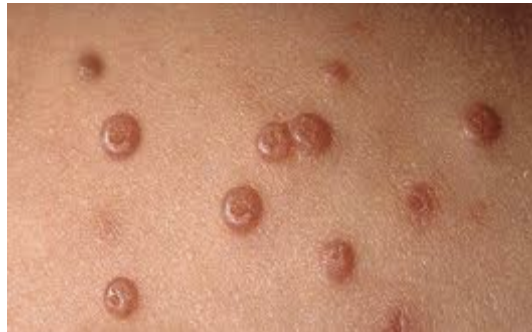Dr. A Francella, Dr N Dilworth 2020/21©

Heat stroke				
Hyponatremia				CBC, lytes, Renal function
Cold-related illnesses				
Hypothermia				
Frost-bite				
Endocrine	# of cases seen	Age/Gender	Sport Type	INVESTIGATION
Diabetes and exercise				
Event Planning	# of cases seen	Age/Gender	Sport Type	INVESTIGATION
Communication				
Equipment				
Personnel				
Environment				
Sport-Specific				
Hematological	# of cases seen	Age/Gender	Sport Type	INVESTIGATION
Iron deficiency				CBC, ferritin
Sickle Cell Anemia				Sickle cell trait, CBC, hemoglobin electrophoresis
Masters Athletes	# of cases seen	Age/Gender	Sport Type	INVESTIGATION
Para Athletes	# of cases seen	Age/Gender	Sport Type	INVESTIGATION
Classification systems				
Autonomic dysreflexia				
Sensory Deficit-related issues				
Pressure sores				
Fractures				
Urinary retention				
Pregnancy and exercise	# of cases seen	Age/Gender	Sport Type	INVESTIGATION
Physiological changes				
Fetal risks				
Fetal benefits				
Pre-participation Screening	# of cases seen	Age/Gender	Sport Type	INVESTIGATION
Relative Energy Deficiency in Sport (RED-S)	# of cases seen	Age/Gender	Sport Type	INVESTIGATION
Renal	# of cases seen	Age/Gender	Sport Type	INVESTIGATION
Acute renal failure				Renal function

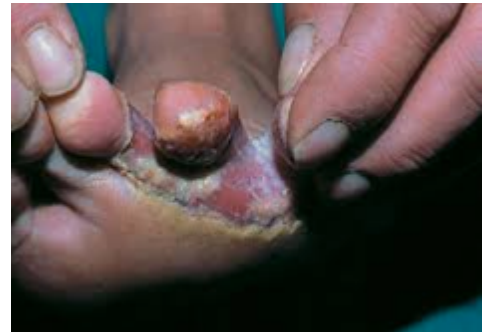Dermatology



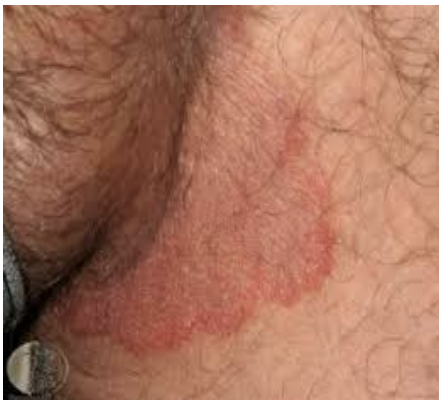Herpes Gladiatorum



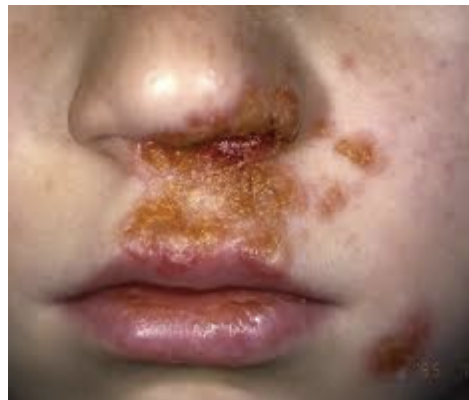Molloscum Contagiosum



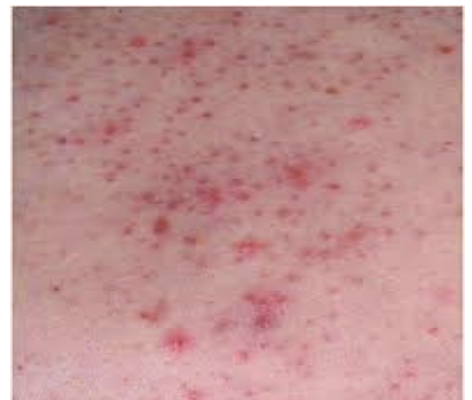Tinea (corporis, capitis, cruris, pedis)



Tinea



Impetigo



Folliculitis

Sports & Exercise Medicine Differential Guidebook©
 Dr. A Francella, Dr N Dilworth 2020/21©

Infection: Viral	# of cases seen	Age/Gender	Sport Type	Treatment	INVESTIGATION
HSV					
Molluscum Contagiosum					
Herpes Zoster Virus					
Tinea corporis					
Tinea capitis					
Tinea pedis					
Bacterial					
Impetigo					
Folliculitis					
Furuncle/Carbuncle					
Cellulitis					
OTHER					
Piezogenic papules					